

A Prospective Observational Study on Ultrasonographic Measurement of Optic Nerve Sheath Diameter as a Bedside Tool in Detecting Findings of Increased Intracranial Pressure in Neuro Critical Care Patients

Ravi Saravanan¹, Krishnamoorthy Karthik², Kanirajan Yogalakshmi³, Prabhuvel Nandhini⁴

^{1,2}Associate Professor, ³Post Graduate, Department of Anaesthesiology, SRM Medical College Hospital and Research Centre, Potheri, Chennai, Tamil Nadu 603203, India. ⁴Consultant, Department of Anaesthesiology, SIMS Hospital, Vadapazhani, Chennai, Tamil Nadu 600026, India.

Abstract

Context: Posttraumatic intracranial hypertension might be detrimental. Bedside ultrasound measurement of optic nerve sheath diameter helps in early diagnosis of increased intracranial pressure. *Aims:* To determine the accuracy of detecting the raised intracranial pressure by ultrasonographic measurement of Optic Nerve Sheath Diameter (ONSD). To correlate ONSD with the Computer Tomography (CT) findings of increased intracranial pressure and the average time taken to measure ONSD with ultrasound. *Settings and Design:* A Prospective, double blinded Observational Study. *Methods and Materials:* To determine the accuracy of detecting the raised intracranial pressure by ultrasonographic measurement of Optic Nerve Sheath Diameter (ONSD). To correlate ONSD with the Computer Tomography (CT) findings of increased intracranial pressure and the average time taken to measure ONSD with ultrasound. *Statistical Analysis:* Descriptive Analysis - Sensitivity, Specificity and Predictive values. *Results:* The sensitivity for the mean binocular optic nerve sheath diameter ultrasonography in detecting elevated intracranial pressure was 99.42% and the specificity was 82.43% with an odds ratio of 0.3547. The positive predictive value was 92.97% and the negative predictive value was 98.39% with an *p* - value of < 0.0001 which was significant. The average time taken to measure the ONSD was 19.8 secs. *Conclusions:* The evaluation of optic nerve sheath diameter is a simple noninvasive procedure, which is a potentially useful tool in the assessment and monitoring of raised intracranial pressure.

Keywords: Bedside ultrasound; Optic nerve sheath diameter; Intracranial hypertension.

How to cite this article:

Ravi Saravanan, Krishnamoorthy Karthik, Kanirajan Yogalakshmi, et al. A Prospective Observational Study on Ultrasonographic Measurement of Optic Nerve Sheath Diameter as a Bedside Tool in Detecting Findings of Increased Intracranial Pressure in Neuro Critical Care Patients. Indian J Anesth Analg. 2020;7(1 Part -I):99-105.

Introduction

Early detection of intracranial hypertension and proper treatment to reduce Intracranial Tension (ICT) protects cerebral perfusion and better neurological recovery.¹ Clinicians need an accurate

tool to distinguish those with elevated intracranial pressure from a vast majority of patients with a head injury who have no elevated intracranial pressure. Direct measurement of CSF pressure by placing intraventricular or intraparenchymal catheters and transducing them is the gold standard

Corresponding Author: Krishnamoorthy Karthik, Associate Professor, Department of Anaesthesiology, SRM Medical College Hospital and Research Centre, Potheri, Chennai, Tamil Nadu 603203, India.

E-mail: karthikkrishnamoorthy1981@gmail.com

Received on 18.10.2019, **Accepted on** 07.12.2019

in the measurement of intracranial pressure. These procedures are highly invasive with complications like hemorrhage, infection, also require technical expertise and availability.²⁻⁵

Other noninvasive methods available to assess intracranial hypertension are neuroimaging (CT and MRI brain), transcranial Doppler, tympanic membrane displacement, intraocular pressure measurement, venous ophthalmodynamometry and changes in optic nerve sheath diameter (ONSD) using orbital ultrasound.⁶

Neuroimaging techniques like CT scan and MRI are most commonly used to predict intracranial hypertension, but these techniques are expensive, require long acquisition times, have limited availability and require patient transport which might be harmful in unstable patients.

Ultrasonography is emerging as a simple bedside tool widely used in emergency departments. The cost of the procedure is low and the equipment is widely available. Ultrasonography of ONSD has been developed in recent times as a possible indicator of intracranial hypertension. The optic nerve is a part of the central nervous system and is surrounded by CSF (Cerebro Spinal Fluid), which is continuous with the intracranial subarachnoid space. Elevation of intracranial pressure is transmitted through this subarachnoid space, especially the retrobulbar segment as shown in (Fig. 1). Dilatation of the optic nerve sheath is shown to be a much earlier manifestation of ICP rise.⁷⁻¹⁰ CSF pressure variations influence the optic nerve sheath diameter in patients with head injuries, children with ventriculoperitoneal shunts, postmortem specimens, intrathecal gelatin infusion models. Bedside measurement of Optic Nerve Sheath Diameter (ONSD) using orbital ultrasound is an effective tool in early diagnosis of intracranial hypertension.

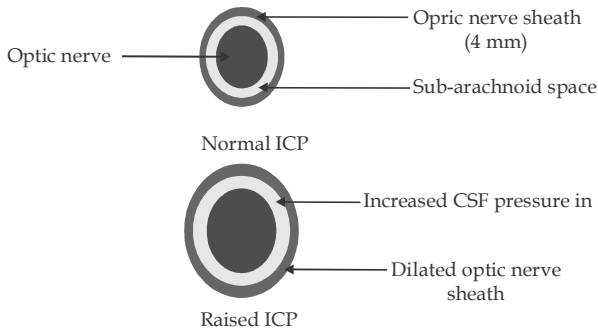


Fig. 1: A cross section of the optic nerve. The subarachnoid space separates the optic nerve from the optic nerve sheath (a) the normal state. (b) After dilatation of the optic nerve sheath as a consequence of increased cerebrospinal fluid pressure in the subarachnoid space. CSF: Cerebrospinal Fluid, ICP: Intracranial Pressure.

The procedure is relatively simple, less time consuming, can be done at the bedside, easily reproducible and with least interpersonal variability in measurements. The patient is placed in the supine position. A layer of gel is applied over the closed upper eyelid. The linear high-frequency 5-10 Hz probe is placed on the gel over the eyeball to get axial images of the globe and optic nerve as in Fig. 2. The diameter of the optic nerve sheath was measured 3 mm behind the globe as in Fig. 3

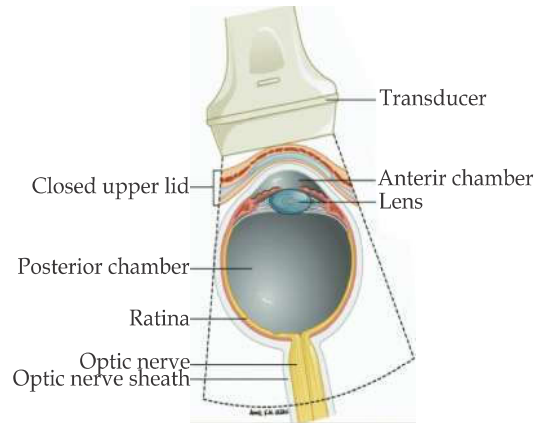


Fig 2: Diagram of sonographic evaluation through closed eyelid of eye and optic nerve sheath diameter.

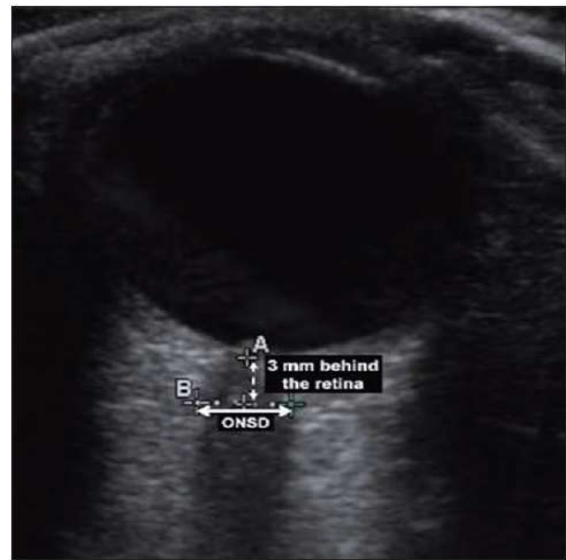


Fig. 3: Ultrasound image showing optic nerve sheath diameter.

Aims and Objectives

The aim is to determine the accuracy of detecting the raised intracranial pressure by ultrasonographic measurement of Optic Nerve Sheath Diameter (ONSD). The primary objective is to correlate ONSD with the Computer Tomography (CT) findings of increased intracranial pressure and the average time taken to measure ONSD with ultrasound.

Materials and Methods

The study is a prospective observational study. After institutional ethical committee approval (IEC NO:1354/2018) and Clinical Trial Registry India registration (CTRI No- 2018/11/022261), this study was done in 233 patients admitted at the emergency department and neurosurgery department meeting the inclusion criteria after getting proper consent. Patients of both sexes between age group 18 and 65 years with a head injury and suspected to have raised ICT and subjected to CT brain evaluation were included in the study. Patients with orbital and ocular injuries and diseases affecting the optic nerve like neuro-inflammatory and degenerative disorders were excluded.

Ocular ultrasound is performed with a linear high frequency 5–10 Hz probe placed over the eyeball to get axial images of the globe and optic nerve. The diameter of the optic nerve sheath was measured 3 mm behind the globe. Binocular ONSD was measured to derive the mean. ONSD values > 5 mm signified increased ICT. The measurements were done by anesthesiologists experienced with ultrasound examination. The time taken for the measurement was noted which is the time from placing the probe over the eyeball to time of arriving the value.

Interpretation

ONSD more than 5 mm is suggestive of increased

intracranial pressure and the values were compared with the CT findings of intracranial hypertension. The patients were followed up subsequently. If the patients undergo repeat CT scan after medical or surgical intervention, ultrasonographic measurement of ONSD was repeated and compared with the new CT findings.

Results

The CONSORT flowchart for the flow of patients is represented in Fig. 4. Two hundred and thirty-three patients were enrolled in the study, 185 Male patients and 48 Female patients were considered for the study. All data were entered in the MS Excel spreadsheet and a descriptive analysis was used as in Table 1. Fig.5 represents the distribution of ONSD among the study patients. The sensitivity for the mean binocular optic nerve sheath diameter ultrasonography in detecting elevated intracranial pressure was 99.42% (95% CI 96.82% to 99.99%) and the specificity was 82.43% (95% CI 71.83% to 90.30%) with odds ratio of 0.3547. The positive predictive value was 92.97% (95% CI 88.98% to 95.59%) and the negative predictive value was 98.39% (95% CI 89.6% to 99.77%) as noted in Table 2. The ONSD correlates well with the CT findings of intracranial tension as represented in the bar diagram in Fig. 7. The average time taken for a single ONSD measurement was 19.8 secs. The scatter diagram for the time taken to measure ONSD is shown in Fig. 6.

Table 1: Table representing the correlation between ONSD and CT findings of raised ICT

	Raised ICT	Normal ICT
ONSD > 5 mm	172 (True positive)	13 (False positive)
ONSD < 5 mm	1 (True negative)	47 (False negative)

Table 2: Stanalysis

Statistics	Value	95% CI
Sensitivity	99.42%	96.82% to 99.99%
Specificity	82.43%	71.83% to 90.30%
Positive Likelihood		
Ratio	5.66	3.45 to 9.27
Negative Likelihood		
Ratio	0.01	0.00 to 0.05
Disease prevalence	70.04%	63.91% to 75.68%
Positive Predictive		
Value	92.97%	88.98% to 95.59%
Negative Predictive		
Value	98.39 %	89.60% to 99.77%
Accuracy	94.33%	90.67% to 96.8

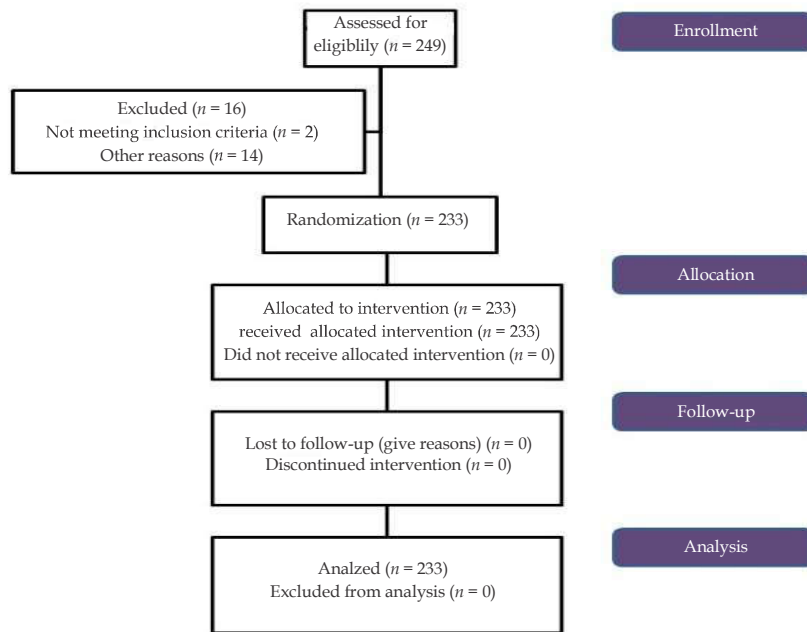


Fig. 4: CONSORT diagram representing the flow of patients in the study.

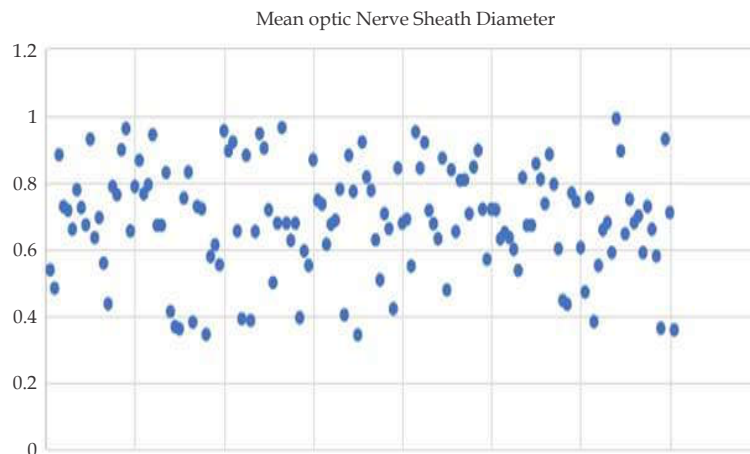


Fig. 5: Scatter diagram representing the distribution of ONSD among study patients.

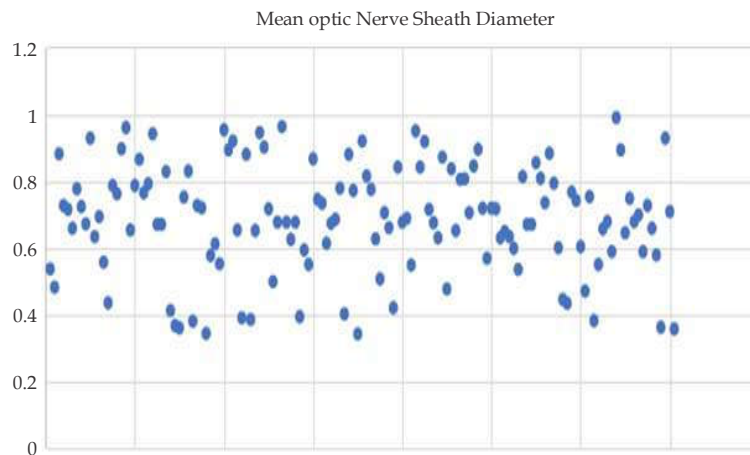


Fig. 6: Scatter diagram representing the time taken for ONSD measurement.

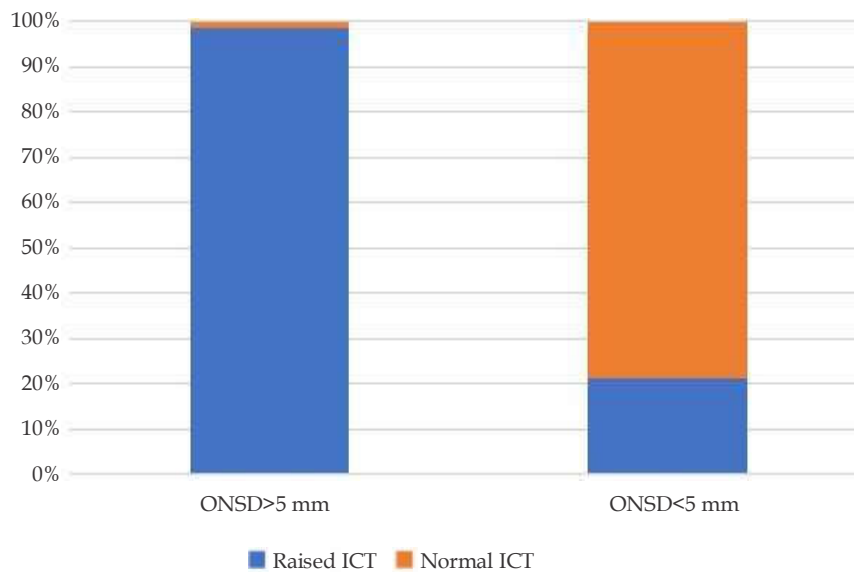


Fig. 7: Bar diagram representing the correlation of ICT with ONSD.

Discussion

Raised intracranial pressure is a consequence of head injury with intracranial bleed which when diagnosed earlier and prompt treatment can avoid cerebral ischemia and its sequel.¹ With this consideration, a test with high sensitivity and specificity with the least time consumption needs to be practiced for early detection of raised ICP.^{17,18} ONS anatomically continues with dura mater from the brain.¹¹ When there is an increase in ICP, the CSF slowly percolates around the nerve sheath causing it to increase in diameter which could be picked up by B scan. A position of 3 mm behind the globe was chosen because the ultrasound contrast is greatest, the results are more reproducible and anatomically the anterior nerve is most distensible. In the present study, the average ONSD in the control group was compared with the group with raised ICP. It was also noted that papilloedema was not found in the acute situation, but that increased ONSD may act as a marker for raised ICP before the development of papilloedema.⁷⁻¹⁰

Using these ultrasonography techniques several groups have investigated the relationship between the optic nerve sheath diameter as measured by A-scan and the ICP. Cennamo¹⁴, Gangemi¹⁵ and Tamburrelli¹⁶ each demonstrated a positive linear relationship between these two variables in neurosurgical patients and in particular, an immediate change in ONSD with the change in ICP.

Liu and Kahn,¹³ in a cadaver study, looked at the pressure gradient within the optic nerve sheath in

relationship to the ICP and the anatomy of the optic nerve sheath. They noted that the trabeculations were most dense posteriorly being quite sparse anteriorly where the nerve sheath was thinnest and the most distensible. Although they did not measure the optic nerve sheath diameter, they noted that in all of the cadavers the bulbous portion of the optic nerve was seen to bulge or inflate somewhat as the intracranial pressure was created, but there was no obvious change in appearance along the remaining nerve.

Hansen and coworkers in 1994 presented data using a transorbital B-scan approach for the measurement of ONSD.^{11,12} This approach allowed them to choose a distance behind the globe to consistently measure the nerve, something difficult to attain with A-scan techniques.

In 1996, Helmke and Hansen⁷ went on to demonstrate, again in cadaver studies, that the ONSD increased by up to 60% at a distance of 3 mm behind the globe compared with only 35% at 10 mm thus confirming Liu and Kahn's observations. Furthermore, they went on to show that the optimal experimental scanning position was longitudinal (axial) where the least interobserver variability was found although there was no significant difference in measurement by lateral, axial or transverse projection. This latter observation is of importance because transorbital B-scan ultrasonography looking along the optic nerve longitudinally relies on a poorer lateral resolution of the ultrasound pulse, rather than the high-resolution perpendicular approach of

a transverse scan. The average time taken to measure ONSD in our study was 19.8 seconds as in the study done by Venkatakrishna Rajajee et al. who observed the median time required for a cluster of six measurements was from 10 minutes.¹⁹ Direct measurement of CSF pressure by placing intraventricular catheters and transducing them is the gold standard in measurement of intracranial pressure which was not done or compared, is the only limitation of this study.

Conclusion

ONSD is a noninvasive, less time consuming, readily available and easily trainable modality to assess raised ICP in suspected patients. There was a significant correlation between the ONSD measured by ultrasonography and CT findings of increased intracranial pressure. ONSD can be considered as a modality to diagnose raised intracranial pressure along with other imaging modality. Though ONSD has a few advantages compared to intraventricular ICP monitoring, a prospective study with a large study population is required to prove ONSD's unequivocal efficacy over intraventricular ICP monitoring.

Key Messages

Optic Nerve Sheath Diameter (ONSD) measured by bedside ultrasound greater than 5 mm in adults indicates raised intracranial pressure. ONSD measurement is less time consuming and correlates well with the Computer Tomographic findings.

References

1. Sekhon MS, McBeth P, Zou J, et al. Association between optic nerve sheath diameter and mortality in patients with severe traumatic brain injury. *Neurocrit Care*. 2014;21(2):245-252.
2. Rosenberg JB, Shiloh AL, Savel RH, et al. Noninvasive methods of estimating intracranial pressure. *Neurocrit Care*. 2011 Dec;15(3):599-608.
3. Binz DD, Toussaint LG 3rd, Friedman JA. Hemorrhagic complications of ventriculostomy placement: A meta-analysis. *Neurocrit Care*. 2009;10(2):253-56.
4. Lozier AP, Sciacca RR, Romagnoli MF, et al. Ventriculostomy-related infections: A critical review of the literature. *Neurosurgery* 2001;51:170-81.
5. Saladino A, White JB, Wijdicks EF, et al. Malplacement of ventricular catheters by neurosurgeons: A single-institution experience. *Neurocrit Care*. 2009;10(2):248-52.
6. Raboel PH, Bartek J, Andresen M, et al. Intracranial pressure monitoring: Invasive versus noninvasive methods: A review. *Crit Care Res Pract* 2012;2012:14.
7. Helmke H, Hansen HC. Fundamentals of transorbital sonographic evaluation of optic nerve sheath expansion under intracranial hypertension. I Experimental study. *Pediatr Radiol* 1996 Oct;26(10):701-705.
8. Helmke H, Hansen HC. Fundamentals of transorbital sonographic evaluation of optic nerve sheath expansion under intracranial hypertension. II Patient study. *Pediatr Radiol* 1996 Oct;26(10):706-710.
9. Hansen HC, Helmke K. Validation of the optic nerve sheath response to changing cerebrospinal fluid pressure: ultrasound findings during intrathecal infusion tests. *J Neurosurg*. 1997;87(1):34-40.
10. Hansen HC, Helmke K, Kunze K. Optic nerve sheath enlargement in acute intracranial hypertension. *Neuro-ophthalmology* 1994;14(6):345-54.
11. Hansen HC, Helmke K. The subarachnoid space surrounding the optic nerves. An ultrasound study of the optic nerve sheath. *Surg Radiol Anat*. 1996;18(4):323-328.
12. Helmke K, Hansen HC. Fundamentals of transorbital sonographic evaluation of optic nerve sheath expansion under intracranial hypertension II. Patient study. *Pediatr Radiol*. 1996;26(10):706-710.
13. Liu D, Kahn M. Measurement and relationship of subarachnoid pressure of the optic nerve to intracranial pressures in fresh cadavers. *Am J Ophthalmol*. 1993;116(5):548-556.
14. Cennamo G, Gangemi M, Stella L. The correlation between endocranial pressure and optic nerve diameter: An ultrasonographic study. *Ophthalmic Echography* 1987;7:603-606.
15. Gangemi M, Cennamo G, Maiuri F. Echographic measurement of the optic nerve in patients with intracranial hypertension. *Neurochirurgica* 1987 Mar;30(2):53-55.
16. Tamburelli C, Aricle C, Mangiola A. CSF dynamic parameters and changes of optic nerve diameters measured by standardized echography. *Ophthalmic Echography* 1993;13:101-109.
17. Bäuerle J, Nedelmann M. Sonographic assessment of the optic nerve sheath in idiopathic intracranial hypertension. *J Neurol*. 2011;258(11):2014-2019.
18. Geeraerts T, Merceron S, Benhamou D, Vigué

- B, Duranteau J. Non-invasive assessment of intracranial pressure using ocular sonography in neurocritical care patients. *Intensive Care Med.* 2008;34(11):2062–2067.
19. Rajajee V, Fletcher JJ, Rochlen LR, Jacobs TL. Comparison of accuracy of optic nerve ultrasound for the detection of intracranial hypertension in the setting of acutely fluctuating vs stable intracranial pressure: post-hoc analysis of data from a prospective, blinded single center study. *Crit Care.* 2012;16(3):R79.

